

 STEOMycin V™

 STEOMycin T™

CASE STUDY  
Osteitis

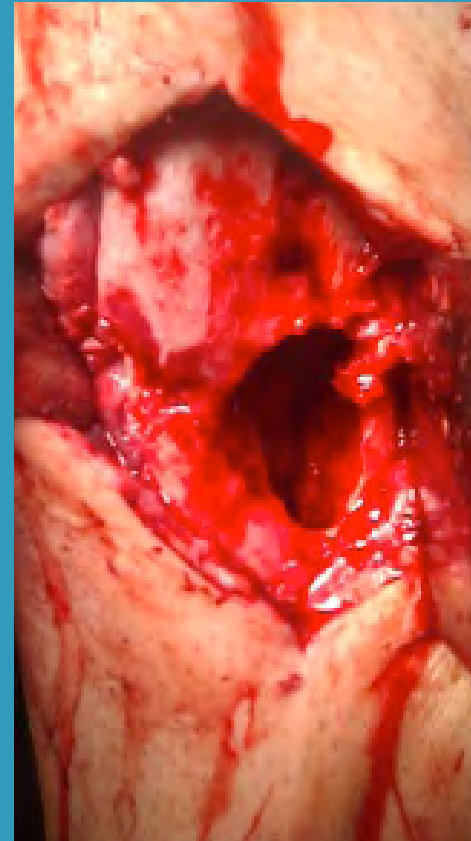
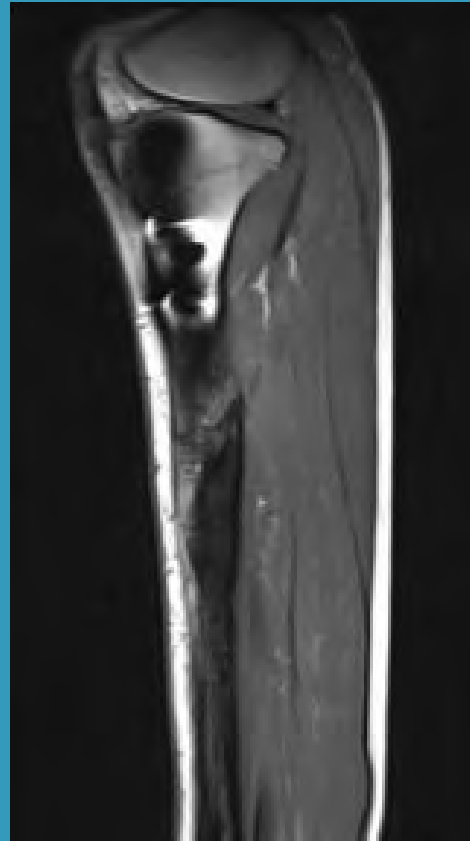
Case M.A.

19yr old male, motorcycle accident with 1° open fracture right tibia, supplied with intramedullary nail one day after trauma, postoperative infection 1.

1 month bedrest and i.v. antibiotics.

6months after trauma removal of 1 interlocking screw. Non union, ongoing infection.

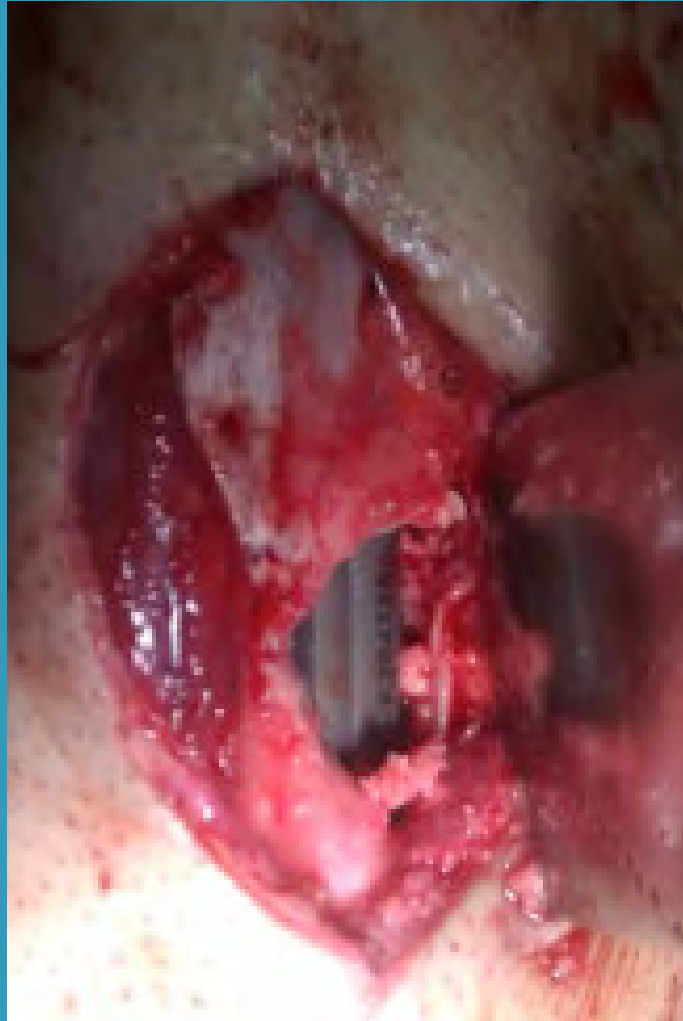8 months after trauma acute infection with septicaemia. Suppressive therapy with oral antibiotics.



Preoperative MRI: infected pseudarthrosis

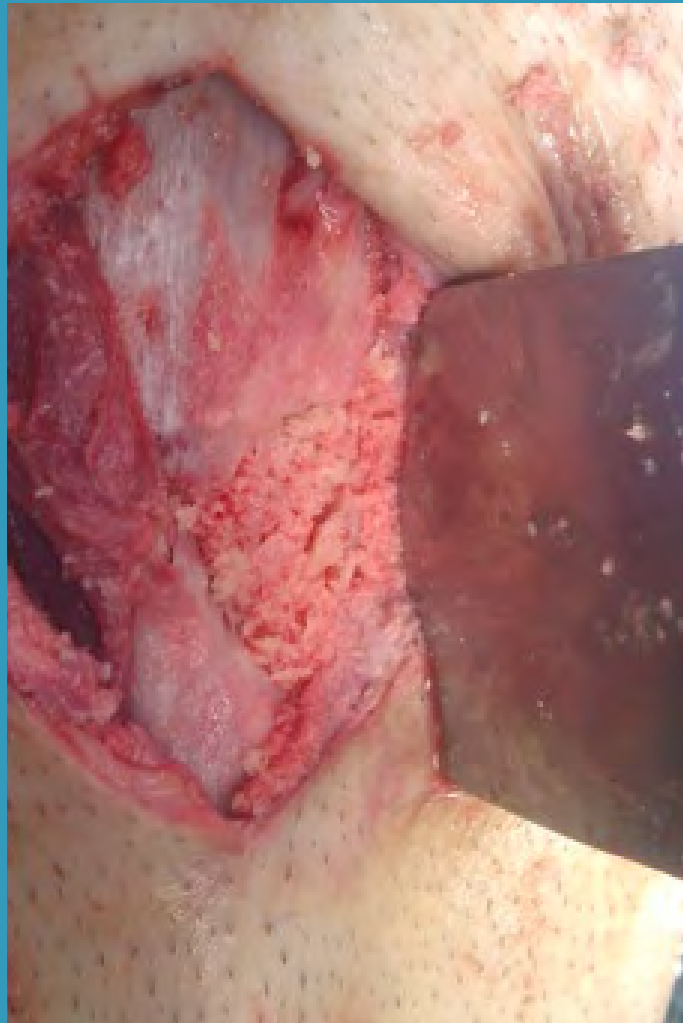intraoperative situation: osseous defect 3-5cm

Intraoperative situation after  
debridement and exchange  
of intramedullary nail





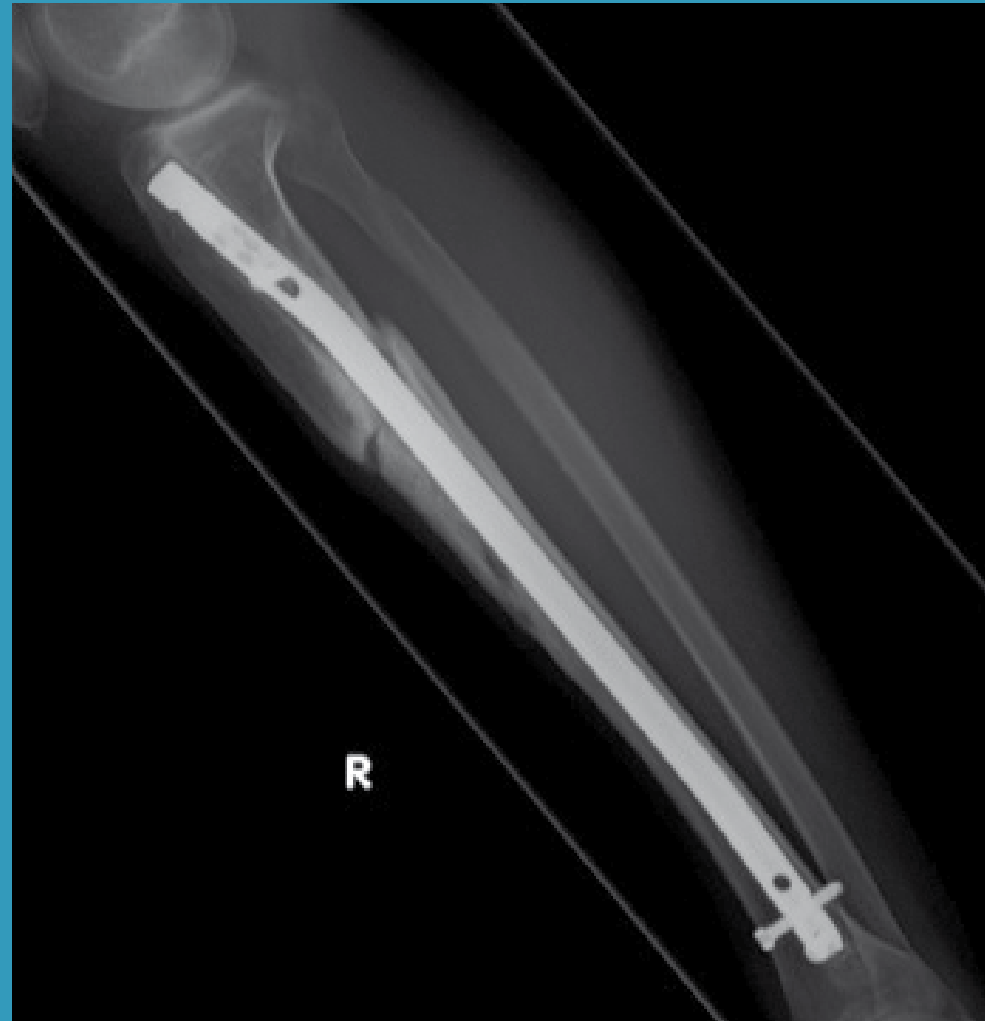Intraoperative situation after  
reconstruction with OSTEOmycin™.



CASE STUDY  
Osteitis




Post-op X-ray: ▶



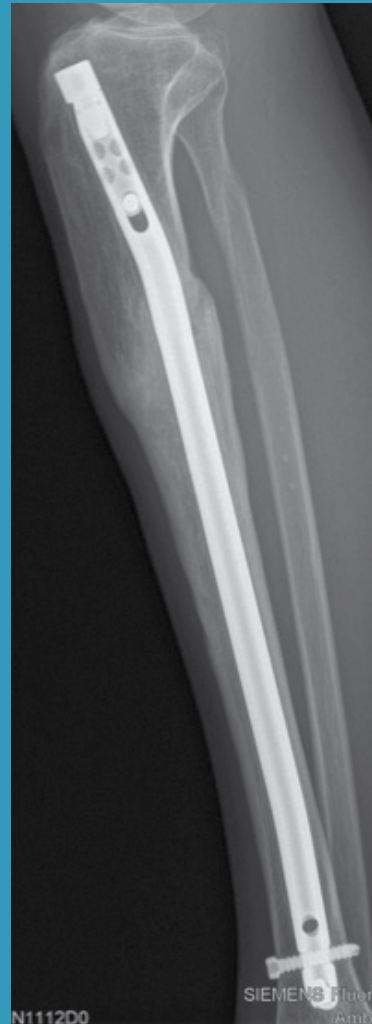CASE STUDY  
Osteitis



5 months postop ▶



10months postop. ▶



Osteomycin may favourably be used in one stage exchange of infected endoprotheses.

The high local antibiotic concentrations avoid re-contamination of new implants and is remodelled to new own bone.